

REC: CardioClinics

www.reccardioclinics.org

Image in cardiology

**Cor triatriatum sinistrum in adulthood:
A case report****Cor triatriatum sinistrum en la edad adulta: un caso clínico**Margarida Cabral^{a,*}, Luís Graça Santos^a, Catarina Ruivo^a, João Morais^b^a Department of Cardiology, Leiria Local Health Unit, Leiria, Portugal^b Centre for Innovative Care and Health Technology (ciTechCare), Polytechnic University of Leiria, Leiria, Portugal

ARTICLE INFO

Article history:

Received 3 November 2024

Accepted 20 November 2024

Available online xxx

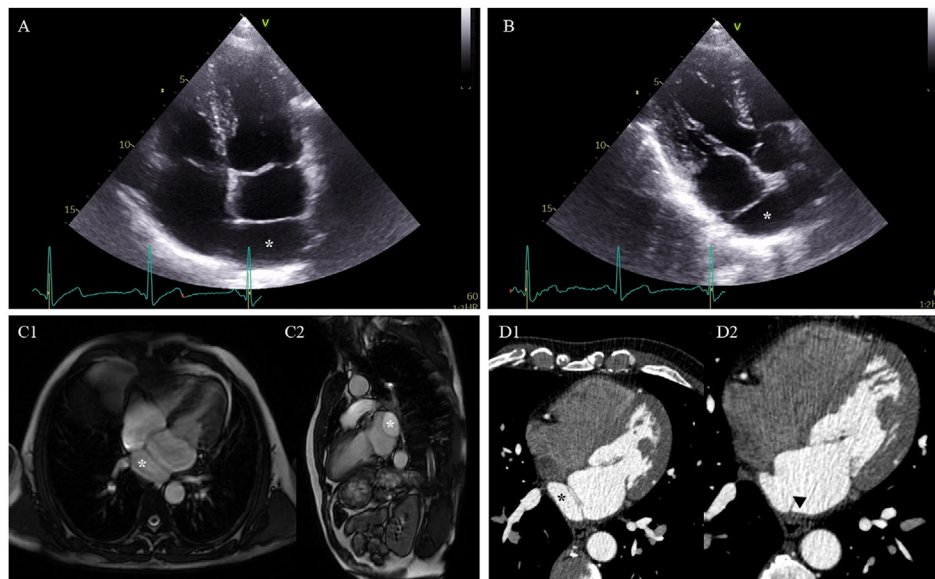


Fig. 1

* Corresponding author.

E-mail address: anamargaridacabral@outlook.pt (M. Cabral).

X @margcabral (M. Cabral).

<https://doi.org/10.1016/j.rccl.2024.11.002>

2605-1532/© 2024 Sociedad Española de Cardiología. Published by Elsevier España, S.L.U. All rights are reserved, including those for text and data mining, AI training, and similar technologies.

Please cite this article in press as: Cabral M, et al.. *Cor triatriatum sinistrum* in adulthood: A case report. REC CardioClinics. 2024. <https://doi.org/10.1016/j.rccl.2024.11.002>