






Letters to the Editor

The value of choroidal thickness in diabetic macular oedema is contradictory

António Campos,^{1,2,3,4} 
 Elisa J. Campos,^{1,2,5} 
 João Martins,^{1,2,6,7} 
 António Francisco Ambrósio^{1,2,5}  and
 Rufino Silva^{1,5,8} 

¹Coimbra Institute for Clinical and Biomedical Research (iCBR), University of Coimbra, Coimbra, Portugal; ²University of Coimbra Center for Innovative Biomedicine and Biotechnology (CIBB), Coimbra, Portugal; ³Department of Ophthalmology, Centro Hospitalar Leiria EPE, Leiria, Portugal; ⁴ciTechCare, Center for Innovative Care and Health Technology, Polytechnic Institute of Leiria, Leiria, Portugal; ⁵Association for Innovation and Biomedical Research on Light and Image (AIBILI), Coimbra, Portugal; ⁶Coimbra Institute for Biomedical Imaging and Translational Research (CIBIT), University of Coimbra, Coimbra, Portugal; ⁷Instituto de Ciências Nucleares Aplicadas à Saúde (ICNAS), University of Coimbra, Coimbra, Portugal; ⁸Department of Ophthalmology, Centro Hospitalar e Universitário de Coimbra (CHUC), Coimbra, Portugal

doi: 10.1111/aos.14529

Editor,

The choroidal thickness (CT) or the subfoveal choroidal thickness (SFCT) have been indicated as prognostic factors for the treatment of diabetic macular oedema (DMO), including in recent works (Mathis et al. 2020; Endo et al. 2020). Authors usually engage the decrease in CT and the decrease in central retinal thickness (CRT) under the action of anti-vascular endothelial growth factor (VEGF) agents, in a cause-effect relationship. Therefore, it is common to see the conclusion that the CT is a marker of DMO outcome. One has to consider that the VEGF action through its receptors 1 and 2 may be independent in the retina and in the choroid and

acting in different cell types, including pericytes (Fig. 1), Müller cells (MC) and the fenestrated pores of the choriocapillaris (Daruich et al. 2018). The association of VEGF-dependent thinning of the retina and thinning of the choroid may be appealing, but they may be just two independent actions of the anti-VEGF agents and not necessarily being correlated one another. Drying of the retina is mainly dependent on MC at the retinal level, and of the presence of pores in the fenestrated endothelium of the choriocapillaris at the retinal pigment epithelium (RPE) level. However, while anti-VEGF agents thin the choroid, they reduce the number of pores at the choriocapillaris in a transient way, as demonstrated by electron microscopy studies (Shimomura et al. 2009).

In a prospective work, we found that the anti-VEGF thinning of the choroid has no prognostic value for the treatment of DMO, when we stratify patients by outcome. Choroidal

thickness (CT) decrease was just an indicator of anti-VEGF side effect on the choroid and the time curves of CRT and SFCT did not overlap (Campos et al. 2018).

In the report of Endo *et al.*, if CT increase in DMO was to be dependent on the level of VEGF, as stated by the authors, it is hard to explain why eyes of patients with proliferative diabetic retinopathy had lower CT, despite having higher CRT, than patients with non-proliferative diabetic retinopathy. On the other hand, VEGF levels depend on systemic treatment of diabetes, but the authors did not find that systemic treatment of diabetes significantly changed CT (Endo et al. 2020).

In the work of Mathis et al. (2020), there was a relation of CT increase with the anti-VEGFs' subsiding effect on the choroid, but it was not clear that monitoring CT would be more useful to detect recurrence than monitoring CRT. It is possible that an anti-VEGFs' waning effect on the choroid does not

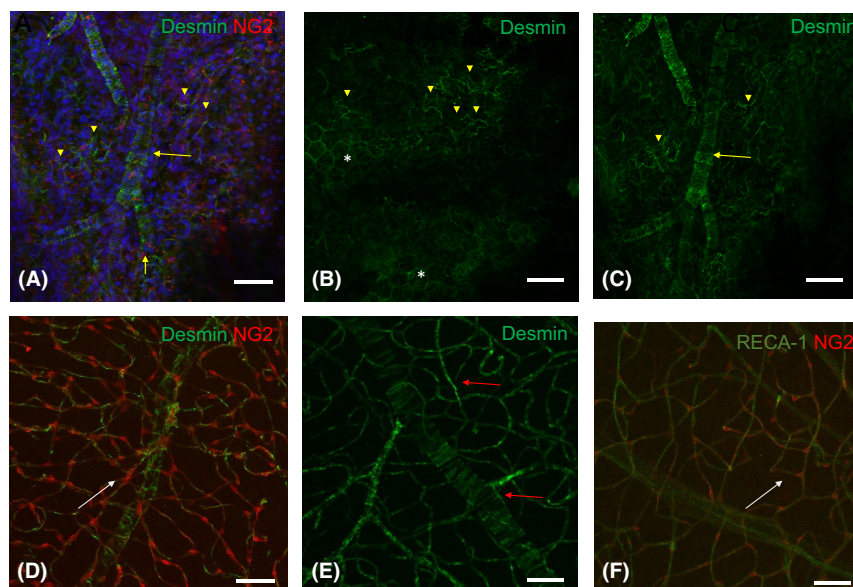


Fig. 1. Pericytes and perivascular mural cells in the choriocapillaris, middle choroid and retina of a 16-week Wistar rat show distinct morphological distribution. (A) Perivascular mural cells immunostained by desmin wrap around choroidal vessels (yellow arrows), while they assume a linear or stellate configuration at the choriocapillaris (arrowheads), corresponding to a scanty non-circumferential distribution of pericytes. NG2 staining of choroidal pericytes shows a sparse distribution. (B) Linear immunostaining of pericytes by desmin (arrowheads) near the hexagonal RPE cells' plane (asterisks) shows a scanty non-circumferential distribution. (C) Distinct morphology of mural cells immunostained by desmin wrapping around choroidal vessels (yellow arrow), while pericytes show a linear morphology and scanty non-circumferential distribution at the choriocapillaris level (arrowheads). (D) NG2 immunostaining of pericytes in the retina displays a perivascular location, even at the retinal capillary network (white arrow). (E) Pericytes and mural cells immunostained with desmin wrap around retinal vessels (red arrows). (F) Retinal vessels immunostained with RECA-1 (rat endothelial cell antibody 1) and pericytes immunostaining with NG2 prove that the location of pericytes in the retinal vessels is always perivascular (white arrow). Scale bar: 50 μ m. 10 \times Full size: x: 850.19 μ m, y: 850.19 μ m.

imply a need for another treatment if the CRT remains stable, that is, changes in CT do not necessarily forecast a DMO recurrence and a need for an additional injection (Mathis et al. 2020). Furthermore, it is to be expected that the choroid thickens as the anti-VEGF effect subsides, because CT decreases as a side effect of anti-VEGF administration (Campos et al. 2018). It would be interesting if the authors would have mentioned the time elapsed from the latest injection before inclusion. Of course, the lack of data on the baseline CT before starting the treatment was also a shortcoming, since unilateral DMO implies that fellow eyes may not be alike.

In conclusion, CT as a surrogate of choroidal inflammation in diabetes, of choroidal flux or of DMO outcome is still under dispute. The value of CT thickening as an indicator of recurrence as the anti-VEGF effect wanes needs further comparison with treated patients that have no recurrence after the anti-VEGF effect subsided. It is debatable whether CT has any advantage over CRT as an indicator of DMO recurrence.

References



- Campos A, Campos EJ, do Carmo A, Patrício M, Castro de Sousa JP, Ambrósio AF & Silva R (2018): Choroidal thickness changes stratified by outcome in real-world treatment of diabetic macular edema. *Graefes Arch Clin Exp Ophthalmol* **256**: 1857–1865.
- Daruich A, Matet A, Moulin A et al. (2018): Mechanisms of macular edema: Beyond the surface. *Prog Retin Eye Res* **63**: 20–68.
- Endo H, Kase S, Takahashi M et al. (2020): Relationship between diabetic macular edema and choroidal layer thickness. *PLoS One* **15**: e0226630.
- Mathis T, Mendes M, Dot C et al. (2020): Increased choroidal thickness: a new indicator for monitoring diabetic macular oedema recurrence. *Acta Ophthalmol*. <https://doi.org/10.1111/aos.14447>.
- Shimomura Y, Hirata A, Ishikawa S & Okinami S (2009): Changes in choriocapillaris fenestration of rat eyes after intravitreal bevacizumab injection. *Graefes Arch Clin Exp Ophthalmol* **247**: 1089–1094.

Received on April 19th, 2020.
Accepted on June 1st, 2020.

Correspondence:

António Campos
Faculty of Medicine
Coimbra Institute for Clinical and Biomedical
Research (iCBR)
University of Coimbra
3000-548 Coimbra
Portugal
Tel: +351 239480200
Fax: +351 239480217
Email: antoniocamposfigueiredo@gmail.com

Variation of choroidal thickness in diabetic macular edema: friend or foe?

Thibaud Mathis,^{1,2}  Corinne Dot,³
Martine Mauget-Fajssse⁴ and Laurent
Kodjikian^{1,2} 

¹Department of Ophthalmology, Croix-Rousse University Hospital, Hospices Civils de Lyon, University of Medicine Lyon 1, Lyon, France; ²UMR-CNRS 5510 Matéis, Lyon 1 University, Lyon, France; ³Department of Ophthalmology, Desgenettes Military Hospital, Lyon, France; ⁴Department of Ophthalmology, Rothschild Foundation, Paris, France

doi: 10.1111/aos.14530

Editor,

We read with great interest António Campos's letter debating on the role of choroidal thickness (CT) in case of diabetic macular oedema (DME). This letter highlights, considering recent papers (Campos et al. 2018; Endo et al. 2020), that the complexity of the CT variation under anti-VEGF treatment is not completely understood as VEGF receptors were found in many cell types and might trigger different actions. Moreover, many systemic conditions can lead to CT changes such as blood pressure or circadian rhythm.

Our group recently published a study showing that CT increased significantly at the time of oedematous recurrence in eyes with a treated DME, whereas it did not change in healthy fellow eyes. We therefore proposed CT as a new indicator of

DME recurrence, that could help clinicians to better monitor treatments (Mathis et al. 2020). The same observation was previously demonstrated in eyes with exudative AMD (Bouteleux et al. 2019). Several hypothetic mechanisms could explain this finding such as the decreased vasodilation of the choroidal vessels due to a reduction of the VEGF-induced nitric oxide synthesis or the decrease of the intrachoroidal exudation. Many other factors might play a role in these choroidal modifications but are still poorly studied. As we found no differences in CT variation between anti-VEGF and DEX implant, the underlying mechanism could be anti-angiogenic but also anti-inflammatory and may probably be due to the penetration of the molecule into all retinal layers, finally reaching the choroidal compartment.

Besides affecting the retina by the rupture of the blood–retinal barrier, diabetes alters the choroidal vessels in different way: atrophy of the choriocapillaris, reduction of choroidal blood flow and vascular wall deformations. In addition to macro- and microangiopathy, diabetic patients have several other complications including peripheral and autonomic neuropathies. Diabetic autonomic neuropathy leads to several complications such as tachycardia or orthostatic hypotension, reflecting the impairment of the cardiovascular autonomic control. Significant peripheral vascular dysfunctions are found in this case and are explained by an imbalance between sympathetic and parasympathetic inputs. However, none of the ocular effects of this dysautonomic syndrome have been described to date.

In addition to intrinsic choroidal neurons, sympathetic (from noradrenergic postganglionic neurons in the superior cervical ganglion) and parasympathetic (presumably from the pterygopalatine ganglion and the ciliary ganglion in mammals) nerves were found in the choroidal space and were thought to adjust the choroidal blood flow by vasoconstriction (sympathetic) or vasodilation (parasympathetic) (Reiner et al. 2018). However, the implication of the autonomous system in the modification of CT